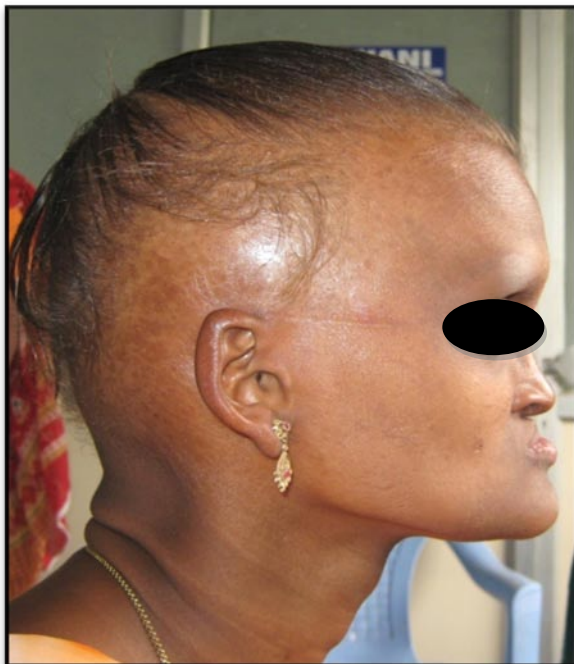
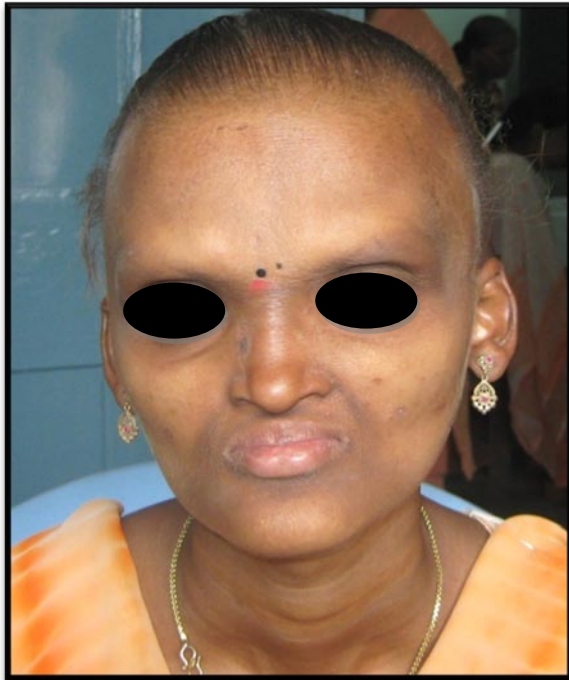
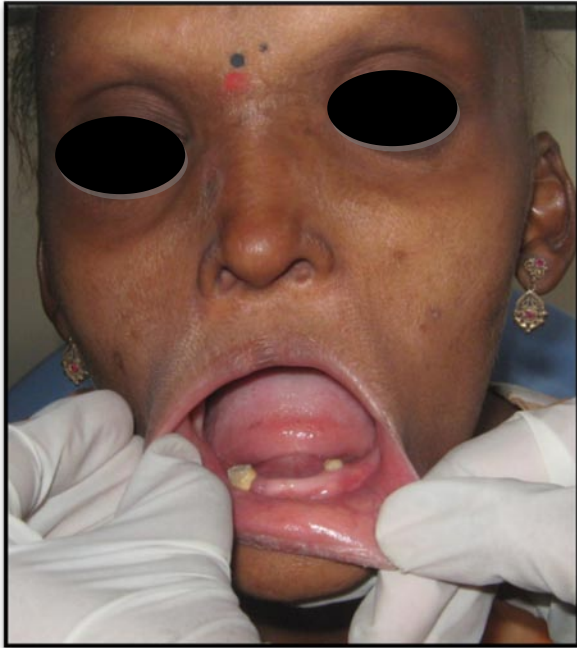ANHIDROTIC ECTODERMAL DYSPLASIA



Clinically showing reduction of middle one third of the face and sparse hair



18 years female complaining with missing teeth

Histopathological picture:

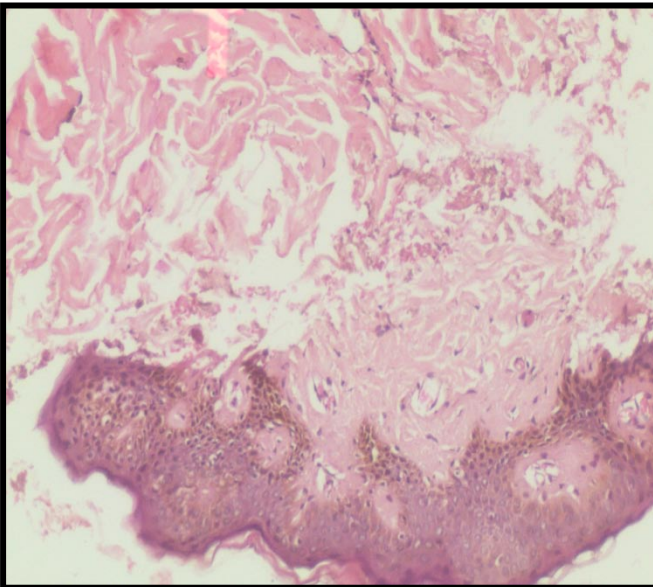


Photo micrograph showing reduction in number of sweat glands, hair follicles & sebaceous glands

Final diagnosis: Anhidrotic ectodermal dysplasia