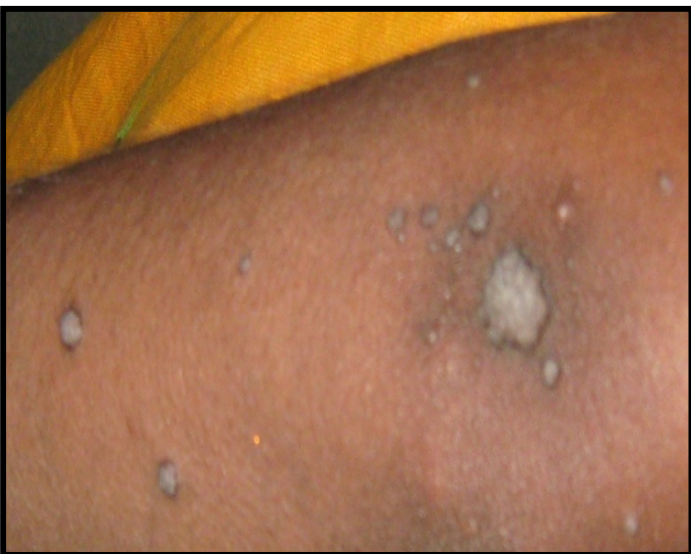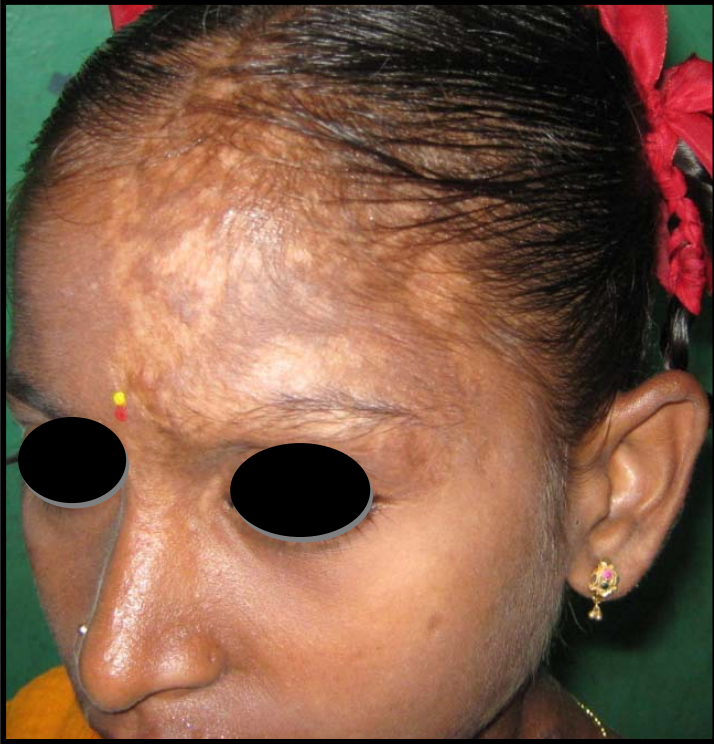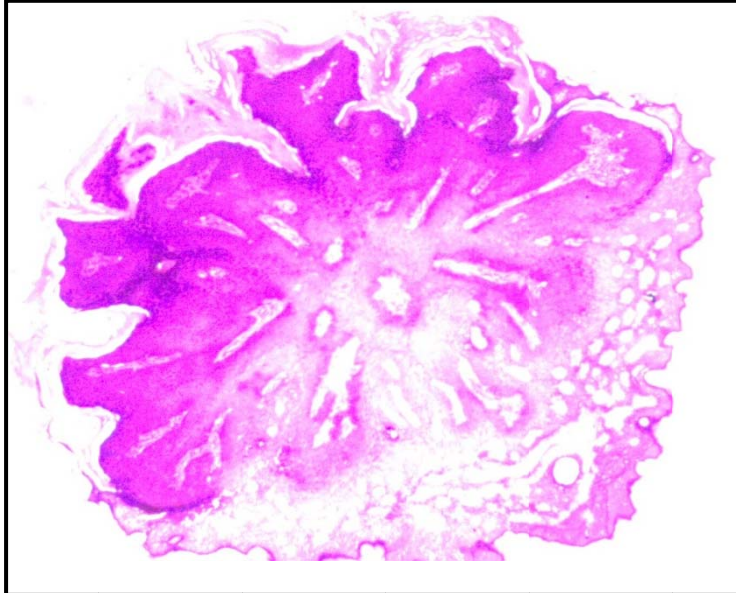


# VERRUCA VULGARIS –A CASE REPORT

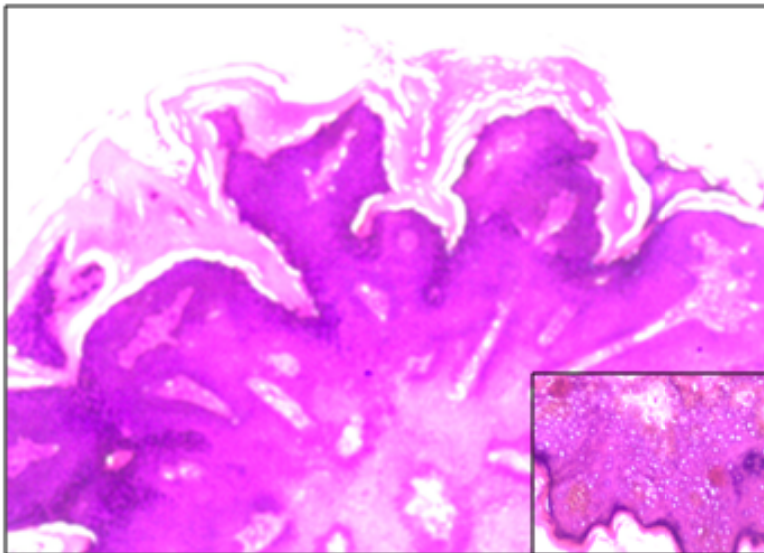
Case – 1



14 year old female complaining with multiple over growth on the fore head and arms



Histopathological features



Photomicrograph showing finger like projections with koilocytes

Final Diagnosis: **Verruca Vulgaris**