

# Maxillary prognathism correction with anterior maxillary osteotomy (Cupar technique)

## Surgeons

Dr. P. S. CHAKRAVARTHI

Dr.S. SUMANTH KRISHNA

## Case history

A 24 year old female patient came with a complaint of incompetent lips, gummy smile and forwardly placed upper front teeth to the SIBAR institute of dental sciences, Takkellapadu, Guntur. On examination we found Angle class I malocclusion, Canine classII, overjet 17 mm, overbite 8mm, gummy smile.

## **Surgical procedure (Anterior maxillary osteotomy {Cupar technique})**

The procedure is carried out under general anaesthesia . Upper first premolars are extracted on either side .Standard Cupar incision was given from first premolar to premolar .The mucoperiosteum is elevated through this incision to expose the anterior wall of the maxilla.

Horizontal osteotomy from one side of incision to opposite side was done. Palatal tunneling was done from the extraction socket. Superior and posterior repositioning was done and fixed with 2 mm “L” shaped plate. Suturing was done .No operative and postoperative complications were observed.

## **Discussion**

The first report of an anterior segmental anterior maxillary osteotomy (ASMO) was published by COHN-STOCK in 1921. After a transverse incision in the palatal mucosa, he made a wedge-shaped osteotomy **palatal** to the anterior teeth. A greenstick fracture was then created at the osteotomy site, and the anterior maxilla was retracted. The anterior segment, however, relapsed within 4 weeks. Since then, the method has been developed and refined. The biologic process of healing of various modifications of this osteotomy has been studied in experimental models. Currently, mainly three variations of ASMO are used; the Wassmund, Wunderer, and downfracture methods.

When the Wassmund method is used, the anterior maxillary segment derives its blood supply from both the facial and the palatal gingiva, as no flaps are raised. The planned osteotomy sites are reached by tunneling under the mucoperiosteum.

The Wunderer method involves a palatal flap raised by means of a transverse incision of the palate. The anterior osteotomy is made after tunneling, leaving the buccal blood supply intact. In the downfracture method, on the other hand, a buccal flap is raised, and the palatal osteotomy is made after tunneling, leaving the **palatal** blood supply intact.

The usual indications for ASMO are excessive vertical or anteroposterior development of the maxillary alveolar process in patients where the relationships between the posterior teeth are acceptable. When superior repositioning of the anterior part of the maxilla is the primary objective, the downfracture method is usually recommended, while the Wunderer method is more practical for posterior repositioning.

The main advantage of the Wassmund method is the excellent postoperative blood supply, and this technique is recommended by some authors for all cases other than those requiring superior repositioning.

We corrected maxillary prognathism with anterior maxillary osteotomy (Cupar technique). No operative and postoperative complications are encountered.


Preoperative photographs frontal view

Oblique view

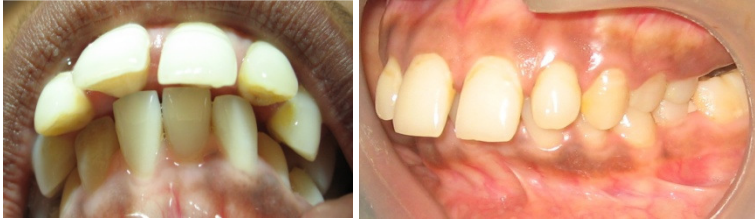

Preoperative photographs on smiling

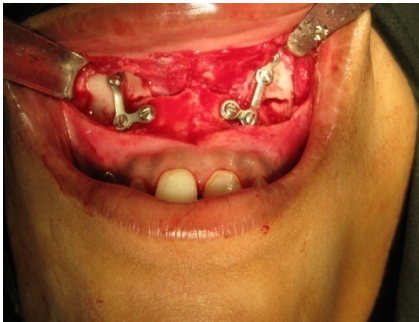Preoperative photographs profile



Intraoral photographs



Anterior maxillary osteotomy – Orthognathic surgery was done



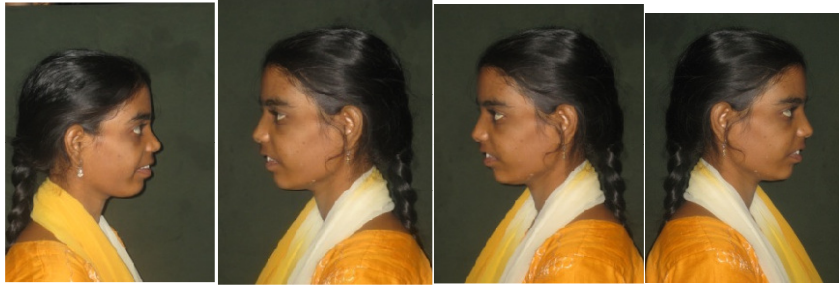Postoperative frontal photograph



Postoperative oblique view photograph



Postoperative profile photograph



## **References**

1. BAUMRIND S, MILLER D, MALTHER R. The reliability of bead film measurements. III. Tracing superimposition. Am J Orthod 1976; 70: 617~14.
2. BELL WH. Revascularization and bone healing after anterior maxillary osteotomy: a study using rhesus monkeys. J Oral Surg 1969; 27:249 57.
3. BELL WH, PROFFIT WP. Maxillary excess. In: BELL WH, PROFFIT WP, WHITE RP, eds.: Surgical correction of dentofacial deformities. Philadelphia: WB Saunders, 1980: 23~41.
4. COHN-STOCK G. Die chirurgische Immediatregulierung der Kiefer, speziell die chirurgische Behandlung der Prognathie. Vjschr Zahnheilk Berlin 1921; 37: 320.
5. CUPAR [. Die chirurgische Behandlung der Form- und Stellungs-Veränderungen des Oberkiefers. Ost Z Stomat 1954; 51:565; Bull Soc Cons Acad RPF Jugosl 1955; 2: 60.
6. EPKER BN. A modified anterior maxillary osteotomy. J Max-Fac Surg 1977; 5:35 8.
7. GRANITE EL. Oronasal fistula following anterior maxillary osteotomy. J Oral Surg 1975; 33:129 30.
8. HAYWARD JR. Surgical correction of anterior open bite. Int J Oral Surg 1987; 7: 286-8.

9. HENDERSON D. A colour atlas and textbook of orthognathic surgery. The surgery of facial skeletal deformity. London:Wolfe, 1985.
10. NELSON RL, PATH MG, OGLE RG, et al. Quantitation of blood flow after anterior maxillary osteotomy: investigation of three surgical approaches. J Oral Surg 1978; 36: 106-11.
11. PEPERSACK WJ. Tooth vitality after alveolar segmental osteotomy. J Oral Maxillofac Surg 1973; 1: 8541.
12. PROFFIT WR, KNIGHT JM. Tongue pressures and tooth stability after anterior maxillary osteotomy. J Oral Surg 1977; 35:798 801.
13. SHER MR. Treatment of oro-antral-nasal fistula after anterior maxillary osteotomy. J Oral Surg 1980; 38:212 14.
14. SVANIER F. Prognathie-Operationen. Z Zahnaerztl Orthop Munchen 1932; 24: 76 9.
15. TURVEY TA, JOURNOT V, EPKER BN. Correction of anterior open bite deformity: a study of tongue function, speech changes, and stability. J Max-Fac Surg 1976; 4: 93 101.
16. WASSMUND M. Lehrbuch der praktischen Chirurgie des Mundes und der Kiefer. Bd I. Leipzig: Meusser, 1935.
17. WESTWOOD RM, TILSON HB. Complications associated with maxillary osteotomies. J Oral Surg 1975; 33:104 15.
18. WUNDERER S. Die Prognathieoperation mittels frontal gestieltem Maxillafragment. Ost Z Stomat 1962; 59: 98-102.